

Reprinted from:

To Dr Dyrce Laumont  
With best wishes Philip Rainbow

© Elsevier/North-Holland Biomedical Press

THE FUNCTIONAL MORPHOLOGY OF THE ALIMENTARY TRACT OF  
BARNACLES (CIRRIPEDIA: THORACICA)

P. S. RAINBOW<sup>1</sup> and G. WALKER

*N.E.R.C. Unit of Marine Invertebrate Biology, Marine Science Laboratories, Menai Bridge,  
Anglesey, U.K.*

**Abstract:** The alimentary tract of barnacles is made up of cuticle-lined foregut and hindgut with intervening U-shaped midgut associated anteriorly with a pair of pancreatic glands and perhaps midgut caeca. Epithelial salivary glands secrete acid mucopolysaccharide, glycoprotein or both. C



AMSTERDAM

## THE FUNCTIONAL MORPHOLOGY OF THE ALIMENTARY TRACT OF BARNACLES (CIRRIPEDIA: THORACICA)

P. S. RAINBOW<sup>1</sup> and G. WALKER

*N.E.R.C. Unit of Marine Invertebrate Biology, Marine Science Laboratories, Menai Bridge,  
Anglesey, U.K.*

**Abstract:** The alimentary tract of barnacles is made up of cuticle-lined foregut and hindgut with an intervening U-shaped midgut associated anteriorly with a pair of pancreatic glands and perhaps midgut caeca. Epithelial salivary glands secrete acid mucopolysaccharide, glycoprotein or both. Cells of all the midgut regions are capable of absorption which is carried out mainly by the anterior midgut and caeca. Midgut cells of *Balanus balanoides* (L.) show a seasonal variation in the distribution of intracellular lipid droplets. Midgut cells rest on an elastic basal lamina and secrete a peritrophic membrane which contains mucopolysaccharide and protein. Cells of the stratum perintestinale connect with the midgut epithelial cells *via* cell processes which probably translocate absorbed materials. Glycoprotein globules and lipid droplets accumulate in the body parenchyma of *B. balanoides* and are transported to the ovaries to form yolk (glycolipovitellin). The pancreatic gland cells of all barnacles are active secretory cells secreting proteinaceous material (probably digestive enzymes).

### INTRODUCTION

In 1948 Törnävä published a detailed account of the structure of the alimentary tract of *Balanus improvisus* and gave a full review of all earlier work on barnacle tracts. Although studies have since been published on specific aspects of the alimentary system of barnacles, such as the salivary glands (see Walley, 1967) and the ultrastructure of the cell layer beneath the midgut epithelium (Koulis, 1971, 1976), no single study has examined the functional morphology of the whole tract using modern techniques. Such a study involving both histochemical and ultrastructural techniques has been made on the British sessile barnacles *B. balanoides* (L.) and *B. hameri* (Ascanius), with briefer comparative studies on a range of other barnacle species. Initial studies confirmed many of Törnävä's findings for *B. improvisus* and his description of the gut of this barnacle has been used as a basis of comparison in this study.

### MATERIALS AND METHODS

#### LIGHT MICROSCOPY

*B. balanoides* were collected monthly from the Menai Strait, and *B. hameri* attached to horse mussels *Modiolus modiolus* (L.), were dredged up off Langness,

<sup>1</sup> Present address: Department of Zoology and Comparative Physiology, Queen Mary College, University of London, London, England.

TABLE I  
Histochemical tests on wax sections.

Test	Significance	Reference
	<i>Proteins and amino acids</i>	
Bromphenol Blue (deamination control)	-NH <sub>2</sub> groups	Mazia <i>et al.</i> (1953)
Diazotization coupling (Diazo.)	Tyrosine	Pearse (1960)
p-Dimethylamino benzaldehyde (DMAB)	Tryptophan	"
2,2'-Dihydroxy-6,6'- dinaphthyl disulphide (DDD)	-SH groups alone	"
DDD (thioglycollate reduction)	-SH and -SS groups	"
DDD (n-ethylmaleimide block and -CN reversal)	-SS groups alone	"
Baker's	Tyrosine	Chayen <i>et al.</i> (1973)
	<i>Carbohydrates</i>	
Periodic Acid-Schiff (PAS)/acetylation control	1 : 2-glycol groups (general carbohydrate)	Casselmann (1962)
PAS/diastase	Glycogen	"
Best's carmine	Glycogen	Pearse (1960)
Mucihematein	Mucin	Laskey (1950)
Hale's dialysed iron	Acid mucopolysaccharides	Pearse (1960)
Alcian Blue pH 1.0	Sulphated mucopoly- saccharides	Pearse (1968)
Alcian Blue pH 2.5	Acid mucopolysaccharides	"
RNAase control	Nucleic acid	"
	<i>Nucleic acids</i>	
Methyl-Green-Pyronin (M-G-P)	RNA and DNA	Pearse (1960)
M-G-P/RNAase control	DNA	"
M-G-P/DNAase control	RNA	"
Feulgen	DNA	"
	<i>Inorganic constituents</i>	
Perls' method	Ferric iron	"
Alizarin Red S	Calcium	"
Calcium Red	Calcium	"
Dithizone	Zinc	"
Benzidine	Copper	"
Rubeanic acid	Copper	"
Molybdate method I	Inorganic phosphate	"
Toluidine Blue	{ Metachromasia	"
Azure A	{ Acid mucopolysaccharide?	Kramer & Windrum (1955)
Ferric chloride	Phenols	Lison (1936)
Basic fuchsin/FeCl <sub>3</sub>	'Elastic' tissue	Horobin <i>et al.</i> (1974)
Spirit Blue	'Elastic' tissue	Elder & Owen (1967)
Oxidation for elastic stain		Gabe (1953)
Heidenhain's Azan	General stain	Gray (1954)

TABLE II  
Histochemical tests on fresh-frozen sections.

Test	Significance	Reference
Sudan Black B in triethylphosphate	General lipid	Pearse (1968)
	<i>Enzymes</i>	
Sodium $\alpha$ -naphthyl phosphate with Fast Violet B coupler	Alkaline phosphatase	Pearse (1960)
Naphthol AS-BI phosphate with Red-Violet LB coupler	Acid phosphatase	"
Naphthol AS acetate with Fast Garnet GBC coupler	Non-specific esterase	Gomori (1952)
L-leucyl $\beta$ -naphthyl-amide with Fast Blue B coupler	Leucine aminopeptidase (protease)	Pearse (1960)
6-bromo-2-naphthyl- $\alpha$ -D-glucopyranoside with Fast Blue B coupler	$\alpha$ -glucosidase (carbohydrase)	"
Catechol	Polyphenol oxidase	Smyth (1954)

Point, Isle of Man, in March and in November. The bodies of these barnacles were quickly dissected from the shells and fixed in Helly's, Zenker's, Clarke's (Carnoy's fluid without chloroform) or sea-water Bouin fixatives. *Elminius modestus* Darwin was also collected from the Menai Strait and *Chthamalus stellatus* (Poli) at Aberffraw, Anglesey. *Lepas anatifera* (L.), *Chelonibia testudinaria* (L.) and *Octolasmis lowei* (Darwin) were all collected near Beaufort, N. Carolina, U.S.A. The bodies of these five barnacle species were fixed in sea-water Bouin only. *Pollicipes mitella* (L.) were collected from Big Wave Bay, Hong Kong and their bodies fixed in Suza. In all cases, the bodies were dehydrated after fixation, embedded in ester wax, and sectioned either transversely or longitudinally at 5 or 7  $\mu$ m. A range of histochemical tests (see Table I) was applied to sections of *Balanus balanoides* and *B. hameri*, and fewer comparative tests on the other species.

Furthermore, fresh bodies of *B. balanoides* and *B. hameri* were supported in sodium carboxymethyl cellulose, quenched in liquid nitrogen and sectioned at 10  $\mu$ m in a cryostat. These fresh-frozen sections were used in histochemical tests to detect lipid and certain enzymes (see Table II). Control sections in the test for lipid were dipped in 1 : 1 chloroform : methanol before staining, and control sections for the enzyme tests were incubated in a medium lacking the enzyme substrate. Fresh-frozen sections were also used in histochemical tests for inorganic constituents (see Table I).

#### ELECTRON MICROSCOPY

Alimentary tracts were dissected from *B. balanoides* collected from the Menai Strait during July, and fixed in 2% OsO<sub>4</sub> in veronal acetate buffer for 1.5 h at 4 °C.

The material was then washed in distilled water (30 min), dehydrated, and embedded in Araldite. Thin sections were cut with glass knives, double stained with uranyl and lead citrate (Pease, 1964) and examined in a GEC-AEI Corinth 275 electron microscope. Thick ( $1\ \mu\text{m}$ ) Araldite sections stained with Toluidine Blue (1% in 1% aqueous borax solution) were examined in the light microscope.

Faecal pellets of *B. balanoides* were fixed and prepared for ultrastructural examination as above.

## RESULTS

As in the case of *B. improvisus* (Törnävä, 1948), the alimentary tracts of all the barnacle species studied here may be divided into three parts – the foregut (stomodaeum), the midgut and the hindgut (proctodaeum). The gut of *Balanus* is U-shaped, terminating at the anus between the sixth pair of cirri. In all, each of a pair of pancreatic glands, of midgut origin, is connected to the swollen anterior portion of the midgut by means of a duct. In *Balanus* branching midgut caeca also connect with the anterior region of the midgut (Törnävä, 1948). Barnacles have a variety of epidermal glands (see Walley, 1967) and two large groups of such glands, the labial and the suboesophageal, probably play an important part in the feeding process (Gruvel, 1893a).

### SALIVARY GLANDS

Salivary glands (Gruvel, 1893a) are groups of epidermal glands which release their secretions through pores in the cuticle (see Walley, 1967). In all species each gland cell has a large nucleus and granular cytoplasm basally, whilst apically there are many discrete granules ( $1\text{--}3\ \mu\text{m}$  diameter) and a few large vacuoles ( $20\text{--}30\ \mu\text{m}$  diameter) with non-granular contents (Fig. 1). The salivary glands consisted of two groups of glands – the labial glands in the labial palps, secreting onto the first maxillae, and the suboesophageal glands at the base of the oral cone and first cirri, secreting into the region behind the oral cone. In contrast Törnävä (1948) described a single group of glands (apparently the labial glands) in *B. improvisus*. In the stalked barnacles, the labial glands were the larger of the two groups of glands.

The histochemical characteristics of the secretions (apical granules) produced by the two glands of *B. hameri* were different (see Table III): the labial glands (stained with Alcian Blue in Fig. 2) secrete an acid mucopolysaccharide and the suboesophageal glands a glycoprotein. In *B. balanoides* the secretions of the two glands were histochemically identical (see Table III) both being glycoprotein in nature as in the case of the suboesophageal gland of *B. hameri*. Fig. 3 shows the apical granules of the labial glands of *B. balanoides* stained positively by the diazo method. In all gland cells the contents of the large vacuoles were histochemically identical to the apical granules.

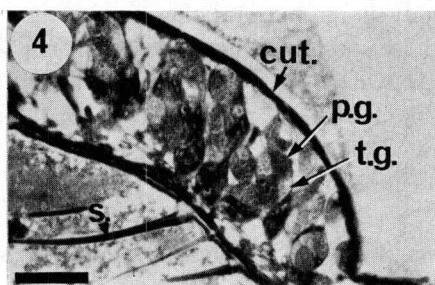
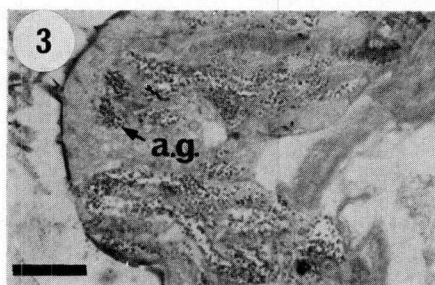
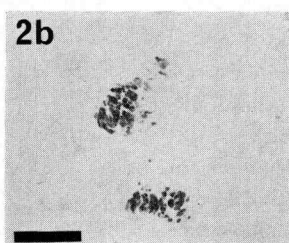
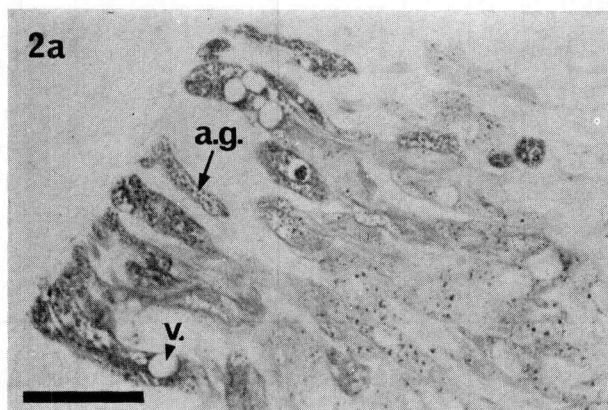
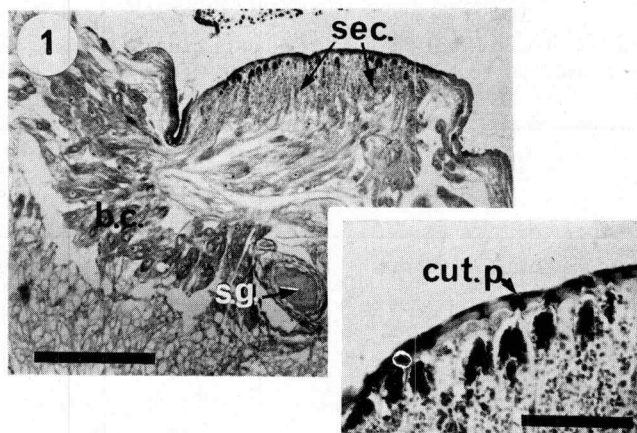


Fig. 1. *Balanus hameri*: suboesophageal salivary gland showing basal cytoplasm (b.c.) and apical secretion granules (sec.); s.g., suboesophageal ganglion; scale bar, 400  $\mu\text{m}$ : inset, cells open through cuticular pores (cut. p.); scale bar, 70  $\mu\text{m}$ .

Fig. 2. *Balanus hameri*: a, part of a labial gland stained with Alcian Blue (pH 1.0); a.g., apical granules, v., vacuole; scale bar, 80  $\mu\text{m}$ ; b, low power showing both labial glands stained with Alcian Blue (pH 2.5); scale bar, 300  $\mu\text{m}$ .

Fig. 3. *Balanus balanoides*: labial gland stained for tyrosine (diazo method) showing positive apical granules (a.g.); scale bar, 40  $\mu\text{m}$ .

Fig. 4. *Lepas anatifera*: section through a labial palp with enclosed labial gland cells stained with Azure A: gland cells in groups of four, two of the four staining darkly (purple) and two cells faintly (turquoise); cut., cuticle; p.g., purple granules; s., seta; t.g., turquoise granules: scale bar, 70  $\mu\text{m}$ .

TABLE III

Histochemical characteristics of the apical granules of barnacle salivary glands: — negative reaction; + weakly positive; ++ positive; +++ strongly positive; ++++ very strongly positive; \*  $\beta$  metachromasia.

Test	<i>Balanus hameri</i>		<i>Balanus balanoides</i>
	Labial glands	Suboesophageal gland	Labial and suboesophageal glands
Bromphenol Blue	—	—	+
Diazo	+	++++	+++
DMAB	—	+	+++
DDD (SH)	—	+	+
DDD (SH/SS)	—	+++	+++
DDD (SS)	—	+	—
Baker's	—	++	+
PAS	+++	++	++
PAS/diastase	+++	++	++
Mucihematein	++	—	—
Hale's	+	+	—
Alcian Blue pH 1.0	++++	—	—
Alcian Blue pH 2.5	++++	—	—
Toluidine Blue	Purple *	Turquoise	Turquoise
Azure A	Purple *	Turquoise	Turquoise
Azan	Blue	Blue/Red/Brown	Blue/Brown

The apical granules of the suboesophageal gland of *Lepas anatifera* stained strongly with the diazo method (tyrosine), indicating proteinaceous material. On the other hand, the granules of the labial gland cells of *L. anatifera* fell into two categories — those stained purple ( $\beta$  metachromasia) by Azure A and those stained turquoise, as shown in Fig. 4. A proportion of these gland cells stained for tyrosine (diazo method) and a proportion (presumably the remainder) for acid mucopolysaccharide (Alcian Blue at pH 2.5). The apical granules of both glands of *Chelonibia testudinaria* gave a positive reaction for the presence of tyrosine (protein).

The salivary glands of both *Balanus* species gave negative reactions for the enzymes given in Table II, with the exception of slight alkaline phosphatase activity.

Fig. 9. *Balanus balanoides*: electron micrograph showing the basal region of anterior midgut epithelium: b.l., basal lamina; m., muscle cell; n., nucleus of epithelial cell: scale bar, 10  $\mu$ m.

Fig. 10. *Balanus balanoides*: electron micrograph showing mature cells (m.c.) in process of extrusion from epithelium of anterior midgut: b.c., basal cell; e.l.v., electron-lucent vacuoles; mic., microvilli: scale bar, 5  $\mu$ m.

Fig. 11. *Balanus balanoides*: electron micrograph showing a mature cell in the apical region of anterior midgut epithelium: e.d.v., electron-dense vacuoles; e.l.v., electron-lucent vacuoles; mic., microvilli; mit., mitochondria; n., nucleus; sph., spherule; t.j., tight junction; v., vesicles: scale bar, 1.5  $\mu$ m.

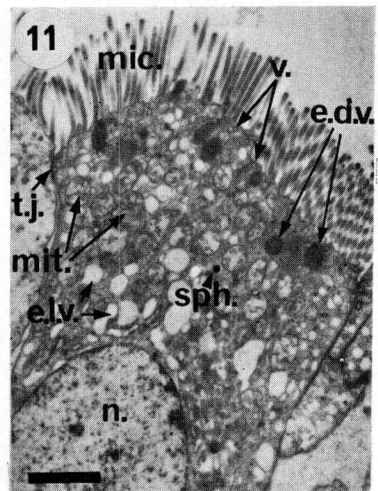
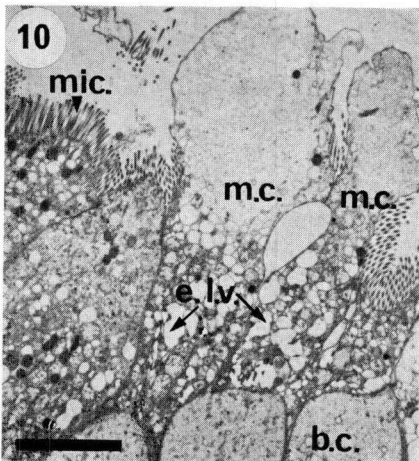
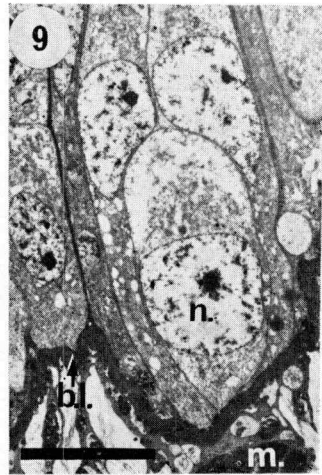
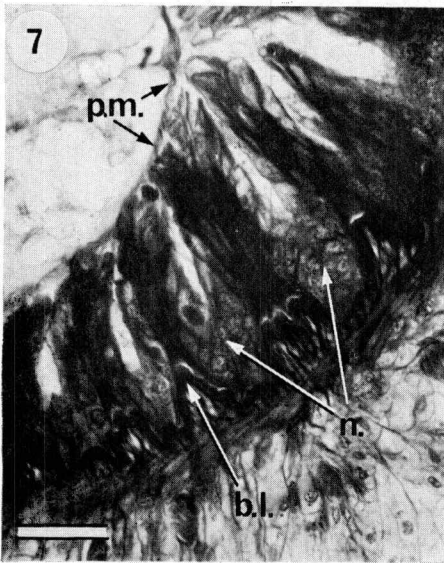
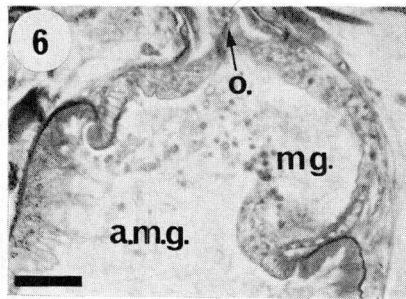
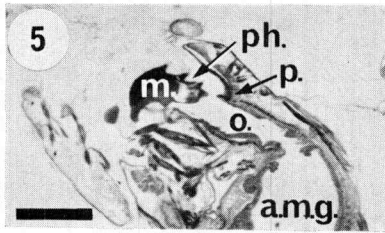
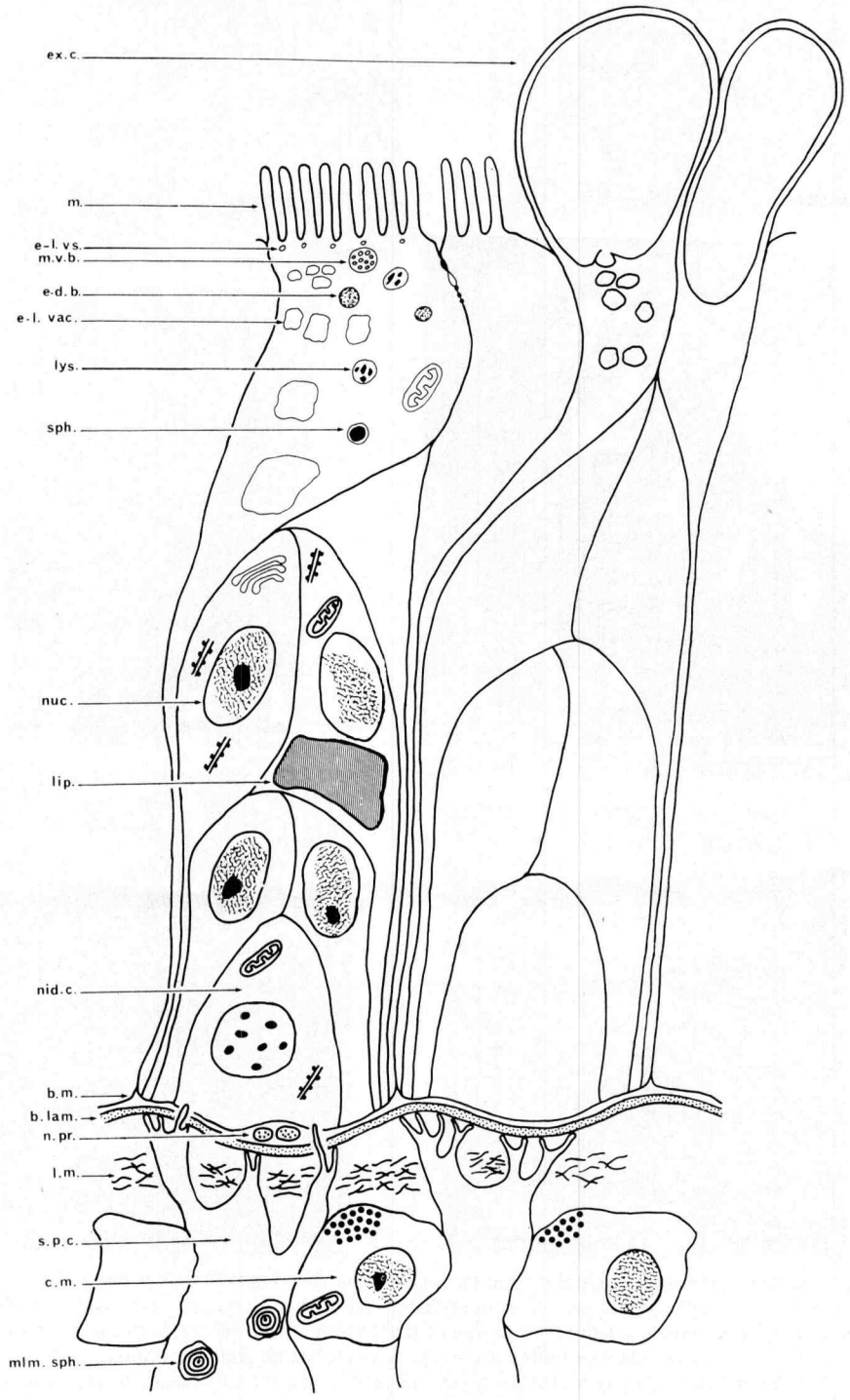


Fig. 5. *Balanus balanoides*: sagittal section through foregut showing the relationship of the mandible (m.) to the paragnathe (p.): a.m.g., anterior midgut; o., oesophagus; ph., pharynx: scale bar, 300  $\mu$ m.

Fig. 6. *Octolasmis lowei*: longitudinal section of the 'Magen'; mg., the region of the foregut leading into the anterior midgut (a.m.g.); o., oesophagus: scale bar, 60  $\mu$ m.

Fig. 7. *Balanus hameri*: highly folded posterior midgut epithelium: b.l., basal lamina; n., nidi; pm., peritrophic membrane: scale bar, 30  $\mu$ m.





## FOREGUT

The cuticle-lined foregut of both *B. balanoides* and *B. hameri* is very similar to that described by Törnävä (1948) for *B. improvisus*, being divided into three portions – the pharynx, the oesophagus and the ventriculus. As may be seen in Fig. 5, the mandible of the barnacle acts against the paragnathe – a region of the wall of the pharynx lined with a particularly thick cuticle. The structure of the foregut of all the Balanomorph barnacles examined is similar to that of *Balanus* but is different in all the stalked barnacles. In *Lepas anatifera*, *Pollicipes mitella*, and *Octolasmis lowei* posterior to the oesophagus the foregut is much expanded to give the “Magen” (Krüger, 1940). There is no ventriculus overlapped by the midgut as in *Balanus*, the foregut passing into the midgut by way of a very wide opening (Fig. 6). A paragnathe is present in each of the stalked species but the pharynx is very short and the mouthparts pass food material almost directly into the oesophagus.

In both *Balanus* species the histochemical characteristics of the cells of the foregut which is ectodermal in origin (Törnävä, 1948), are closely correlated with the characteristics of the hypodermal cells underlying the general body cuticle. The cells at times contained glycogen (PAS-diacetate) and were usually positive for alkaline phosphatase apically. Both esterase and acid phosphatase were usually localized in discrete areas apically in the cells. The foregut cells of *B. balanoides*, but not *B. hameri*, sometimes gave a positive reaction for leucine aminopeptidase, but no  $\alpha$ -glucosidase activity was detected in the foregut cells of either species. The cuticle itself was usually stained by carbohydrate-specific stains and showed enzyme activity on only one occasion – the cuticle of the foregut of a *B. hameri* giving esterase-positive regions.

## MIDGUT, MIDGUT CAECA, AND UNDERLYING TISSUES

The midgut is the major portion of the cirripede alimentary tract and, as in *B. improvisus* (Törnävä, 1948), in both *B. balanoides* and *B. hameri* gives rise anteriorly to seven midgut caeca or diverticula (coeca hepatica, Törnävä, 1948) and a pair of pancreatic glands (glandulae pancreaticae, Törnävä, 1948). The midgut itself is often separated into two parts (see Törnävä, 1948, for literature review) – the anterior midgut (the swollen anterior portion) and the posterior midgut. Törnävä separated the two midgut regions because, 1) the anterior midgut alone is connected to the caeca and the pancreatic glands, and 2) the anterior midgut epithelium shows more physio-

Fig. 8. *Balanus balanoides*: diagram of the anterior midgut epithelium showing a basal nidus cell (nid. c.) which divides to give rise to cells which pass apically but do not lose their connection with the basement membrane (b.m.): these cells eventually extruded into the tract lumen: basement membrane lies on a thick basal lamina (b. lam.) beneath which there are longitudinal (l.m.) and circular (c.m.) muscle zones: specialized cells of the stratum perintestinale (s.p.c.) protrude through the muscle layers and send processes through the basal lamina to make contact with the epithelial cells: e-d.b., electron-dense body; e-l. vac., electron-lucent vacuole; e-l.vs., electron-lucent vesicle; ex.c., extruding cell; lip., lipid; lys., lysosome, m., microvilli; mlm. sph., multilamellate spherule; m.v.b. multivesicular body; n.pr., neural process; nuc., nucleus of epithelial cell; sph., spherule.

logical evidence of secretion. No evidence was found in any species for Törnävä's second criterion, but the division into anterior and posterior midgut is maintained for convenience.

The midgut caeca are blind-ending tubules passing both anteriorly and posteriorly from their wide connections with the anterior midgut. Each of the caeca named by Törnävä (1948) for *B. improvisus* may be identified in both *Balanus* species and also in *Elminius modestus*. Caeca were not present in *Balanus balanoides* thirty days after settlement and so presumably develop as the barnacle grows. Midgut caeca were absent from the balanomorph barnacles *Chthamalus stellatus* and *Chelonibia testudinaria* and from the stalked barnacles *Octolasmis lowei* and *Pollicipes mitella*. Small *Lepas anatifera* did not have midgut caeca but in large individuals there were certainly five and possibly seven branching caeca.

The epithelium lining both the anterior and posterior midgut and the midgut caeca is of one common type. At the light microscope level the epithelial cells are seen to rest on a thick basal lamina beneath which there are small longitudinal muscles within an outer ring of circular muscle (Törnävä, 1948). The muscles surrounding the caeca are thin compared with those around the midgut itself, and at the posterior end of the midgut there is an additional external concentric ring of longitudinal muscle blocks. The midgut epithelial cells of *B. hameri* clearly pass through the cell cycle described by Monterosso (1923) for the midgut cells of *B. perforatus*. Cells are formed in centres of proliferation (nidi), pass to either side as columnar cells and abut against mature cells from adjacent nidi. Mature cells are ejected from the epithelium to be replaced by newly formed cells. The midgut epithelium of *B. hameri* often appeared folded (Fig. 7), the nidi containing young cells present in the crypts and the mature cells at the crests of the folds. The same cycle of cell formation was found in the midgut epithelia of all species examined but in some species (e.g., *B. balanoides*) the epithelium was rarely folded. In *B. balanoides* there is, therefore, no separation into crests and the epithelium, of uniform height, appears stratified. The mature cells form a darkly staining area apically.

The structure of the midgut epithelium of *B. balanoides* is more easily made out at the electron microscope level, and Fig. 8 is a schematic representation of the fine structure. Small basal cells divide and give rise to cells which pass apically so forming an apparently stratified epithelium. These cells do not, however, lose their connection with the basement membrane and the regions between adjacent nidi consist mostly of closely appressed membranes (Fig. 9). The more mature cells come to occupy the apical area of the epithelium and are lined with microvilli which are lost before the cells are finally expelled into the midgut lumen (Fig. 10). There were many small vesicles (0.5  $\mu\text{m}$  diameter) with electron-lucent contents close to the bases of the long (2.5  $\mu\text{m}$ ) microvilli of the mature cells. Similar vacuoles with electron-lucent contents (seen in Fig. 11) were also present throughout the cells and ranged in diameter from 0.1 to 1.0  $\mu\text{m}$ . The most apical vacuoles were the smallest and there was a progressive increase in size basally, suggesting uptake of materials into the cell.

The mature cells also contained further vacuoles, either with heterogeneous contents (lysosomes, 0.2  $\mu\text{m}$  diameter) or with compact electron-dense contents (0.2–0.5  $\mu\text{m}$  diameter), many mitochondria, multivesicular bodies (0.2–0.6  $\mu\text{m}$ ) and free ribosomes. On rare occasions, these cells also contained small vacuoles with a single electron-dense spherule (0.1–0.3  $\mu\text{m}$  diameter). Tight junctions were present between the apical mature cells. As the cells continue to mature they come to contain a large number of lysosomes and before releasing the contents they become packed with vacuoles which finally coalesce (Fig. 10). At times the more basal cells in the epithelium contained lipid droplets and Golgi bodies which appeared to be giving vacuoles with electron-lucent contents. Nuclei were not usually present in sections of the apical cells but were always present more basally, especially in the nidi where they were at times fixed during the state of division. There was a limited infolding of the basement membrane.

The cells of the midgut epithelia of both *B. balanoides* and *B. hameri* contained RNA (M-G-P) and sometimes glycogen (Best's carmine or PAS-diacetate). In *B. balanoides* the epithelial cells of both midgut regions and the midgut caeca at times contained lipid droplets but their size and distribution varied seasonally. The midgut contained no lipid droplets in March 1974 but a month later the epithelium of all regions contained large droplets up to 35  $\mu\text{m}$  diameter (Fig. 12). In May and June lipid droplets were still present in all regions but were much reduced in size (June, maximum diameter 5  $\mu\text{m}$ ). In July, August, and September droplets (1–2  $\mu\text{m}$  diameter) were found only in the anterior midgut and caeca, and by October the midgut was free of all lipid. Droplets (up to 6  $\mu\text{m}$  diameter) re-appeared in the cells of the anterior midgut and caeca in November, but no lipid was present between December 1974 and February 1975. Lipid droplets (up to 5  $\mu\text{m}$  diameter) were again present in the epithelium of all midgut regions in March 1975. When *B. hameri* were collected in March and November the midgut cells of all regions contained lipid droplets (Fig. 13).

In the epithelia of the anterior midgut and midgut caeca of both *Balanus* species, there were discrete regions (lysosomes) positive for the hydrolytic enzymes esterase and acid phosphatase. Weak alkaline phosphatase activity was usually present apically in these epithelia which were, however, negative for both  $\alpha$ -glucosidase and leucine aminopeptidase. Discrete regions of acid phosphatase and esterase activity were also present in the posterior midgut epithelia of both species and which also contained strong, diffuse esterase activity apically. Alkaline phosphatase activity was again present apically and the posterior midgut epithelia of both species were negative to leucine aminopeptidase. On rare occasions the general cytoplasm of the posterior midgut epithelium of *B. balanoides* gave a positive reaction for  $\alpha$ -glucosidase.

All parts of the midgut of all species are lined internally by the peritrophic membrane (Fig. 7). In *Balanus* this membrane stained positively for both mucopolysaccharides and protein as did the microvillous region of the epithelial cells. The peritrophic membrane was not however readily visible with the electron microscope.

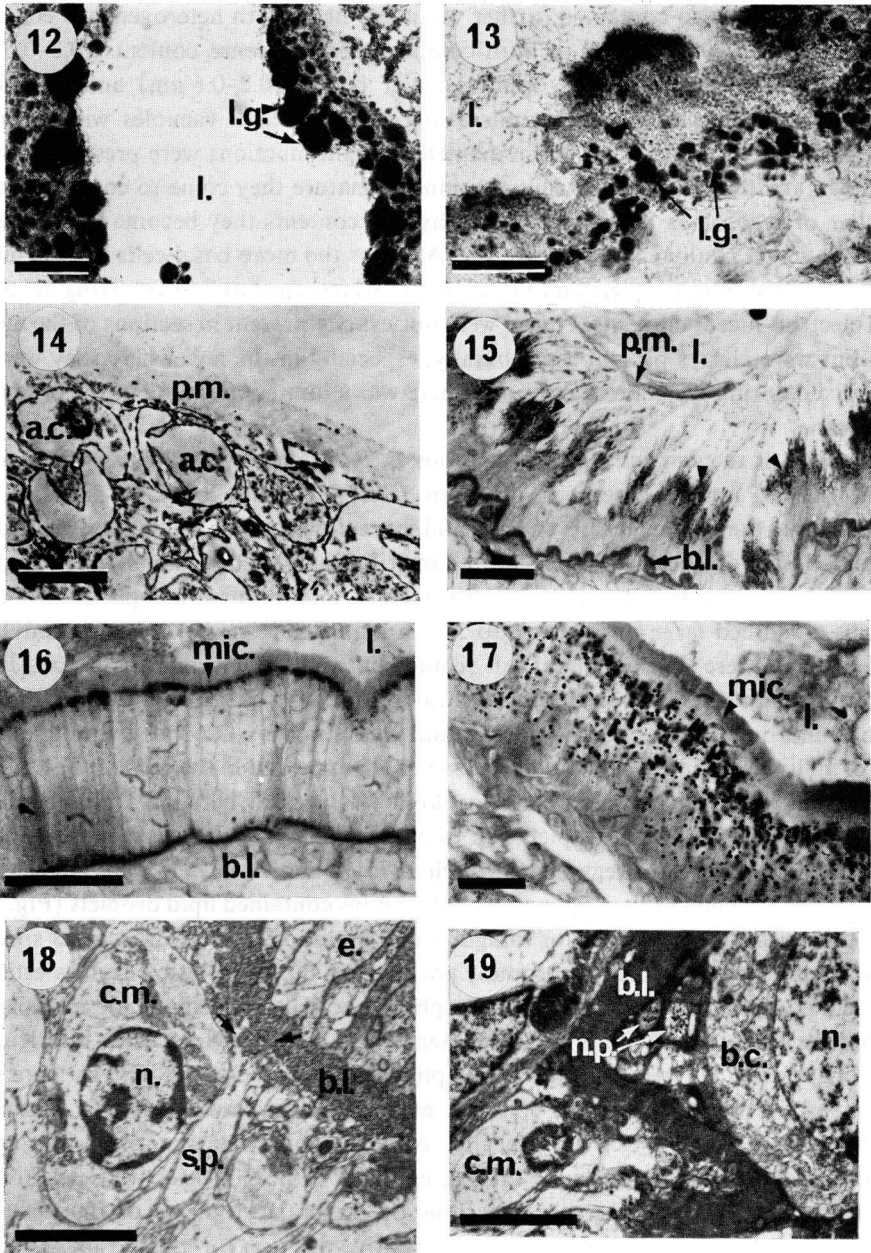


Fig. 12. *Balanus balanoides*: anterior midgut epithelial cells containing Sudan Black B-positive globules (lipid) (animal collected in April, 1974): l., lumen, l.g., lipid globules: scale bar, 70  $\mu\text{m}$ .

Fig. 13. *Balanus hameri*: midgut caecal epithelium stained with Sudan Black B for lipid (animal collected in March, 1974): l., lumen; l.g., lipid globules: scale bar, 20  $\mu\text{m}$ .

Fig. 14. *Balanus balanoides*: electron micrograph showing outer electron-lucent peritrophic membrane (p.m.) in a section of a faecal pellet: a.c., algal cell remnant: scale bar, 3  $\mu\text{m}$ .

TABLE IV

Histochemical characteristics of the apical granules in barnacle posterior midgut cells: - negative reaction; + weakly positive; ++ positive; +++ strongly positive; ++++ very strongly positive.

Test	<i>B. hameri</i>	<i>B. balanoides</i>
Bromphenol Blue	-	-
DMAB	-	-
Diazo	-	-
DDD (SH/SS)	-	-
DDD (SH)	-	-
DDD (SS)	-	-
Baker's	-	-
PAS	++++	++
PAS/diastase	++++	+++
Hale's	++++	+++
Mucihematein	++++	+++
Alcian Blue pH 1.0	+++	++
Alcian Blue pH 2.5	++++	++++
Methyl-Green-Pyronin	-	-
M-G-P/RNAase	-	-
M-G-P/DNAase	-	-
Feulgen	-	-
Perls'	-	-
Alizarin Red	-	-
Azan	Light Blue	Light Blue

Faecal pellets which are enclosed by the membrane were, therefore, examined and Fig. 14 shows the electron-lucent nature of the membrane, a feature that explains its apparent absence from sections of the midgut.

The cells of the most posterior regions of the midgut of both *Balanus* species contained apical granules, 0.5-1  $\mu\text{m}$  diameter (Fig. 15). The histochemical characteristics of these granules (Table IV) indicated that they consist of acid mucopoly-

Fig. 15. *Balanus hameri*: transverse section of the posterior midgut showing peritrophic membrane (p.m.) and apical granules (arrowed) within the epithelial cells: P.A.S. stained: b.l., basal lamina; l., lumen of posterior midgut: scale bar 70  $\mu\text{m}$ .

Fig. 16. *Lepas anatifera*: midgut epithelium cells with positive apical granules (PAS stained): b.l., basal lamina; l., lumen of midgut; mic., microvilli: scale bar 30  $\mu\text{m}$ .

Fig. 17. *Lepas anatifera*: midgut epithelial cells showing granules throughout the cytoplasm, stained with Hale's reagent: l., lumen of midgut; mic., microvilli: scale bar, 15  $\mu\text{m}$ .

Fig. 18. *Balanus balanoides*: anterior midgut: electron micrograph showing processes (arrows) of stratum perintestinale, cell (s.p.) passing through the basal lamina (b.l.): c.m., circular muscle cell; e., epithelial cell; n., nucleus of circular muscle cell: scale bar, 3  $\mu\text{m}$ .

Fig. 19. *Balanus balanoides*: electron micrograph showing neural processes (n.p.) between basal epithelial cell (b.c.) and basal lamina (b.l.) in anterior midgut epithelium: c.m., circular muscle cell; n., nucleus of epithelial cell: scale bar, 3  $\mu\text{m}$ .

saccharide. Similar acid mucopolysaccharide granules were also present in the posterior midgut cells of *Lepas anatifera* (Fig. 16), *Pollicipes mitella*, and *Chelonibia testudinaria*. The midgut cells of *Lepas anatifera* also contained other granules throughout the cytoplasm (Fig. 17); these granules stained strongly with Perls' (indicating ferric iron) and Hale's reagents but were negative to both PAS and Alcian Blue. The positive reaction here to Hale's reagent probably does not indicate acid mucopolysaccharide since this method involves the initial attachment of ferric iron to the mucopolysaccharide and the subsequent localization of this iron. The Perls' positive granules were also present in other barnacles such as *Pollicipes mitella* and *Balanus hameri* but were absent from the midgut cells of *B. balanoides* when viewed under the light microscope.

Beneath the midgut epithelium, the basal lamina (0.6  $\mu\text{m}$  thick in *B. balanoides*) consists of fibrous material (Fig. 18). The lamina has the histochemical characteristics

TABLE V  
Histochemical characteristics of parasoma of the stratum perintestinale cells of *B. hameri*, and of globules in the prosomal parenchyma of summer *B. balanoides*.

Test	<i>B. hameri</i> Parasoma	<i>B. balanoides</i> Prosomal parenchyma globules
Bromphenol Blue	++++	++++
DMAB	—	++++
Diazo	—	++++
DDD (SH/SS)	+++	++++
DDD (SH)	+++	++++
Baker's	—	++++
PAS	++	++++
PAS/diastase	++	++++
Best's carmine	—	—
Hale's	+	+
Mucihematein	—	—
Alcian Blue pH 1.0	—	—
Alcian Blue pH 2.5	+	—
Alcian Blue pH 2.5/RNAase	—	—
Methyl-Green-Pyronin	++++	—
M-G-P/RNAase	+++	—
M-G-P/DNAase	++++	—
Feulgen	+	—
Basic Fuchsin-FeCl <sub>3</sub>	+++	—
Oxidation/Basic Fuchsin-FeCl <sub>3</sub>	+++	—
Toluidine Blue	No metachromasia	Turquoise
Azure A	No metachromasia	Turquoise
Azan	Red	Red

of invertebrate 'elastic' tissue (Elder & Owen, 1967) taking up vertebrate elastic stains only after strong pre-oxidation. Neural processes (0.6  $\mu\text{m}$  diameter) containing electron-dense vesicles were occasionally found between the basement membrane and the basal lamina and are shown in Fig. 19.

Beneath the circular muscle layer surrounding all regions of the midgut there is a specialized cell layer – the stratum perintestinale (Törnävä, 1948). As described by Koulish (1971, 1976) the cells of this layer send processes through the basal lamina to make contact with the midgut epithelial cells (Fig. 18). These cell processes could be detected with the light microscope and stained positively for mucopolysaccharides, probably a feature of the closely adjacent cell membranes. In *B. hameri*, but not *B. balanoides*, the cells of the stratum perintestinale contained glycogen in the spring, and the cell contents of both species stained strongly with mucihematein. The cells also contained globular bodies (parasoma, see Monterosso, 1926, 1927) which were particularly common in *B. hameri*. These parasoma gave a positive reaction to histochemical tests for sulphur-containing proteins and nucleic acids (see Table V). Fresh-frozen sections, Araldite sections of  $\text{OsO}_4$  fixed material, and unstained wax sections of material fixed in Clarke's, all contained spherules (0.5–5  $\mu\text{m}$  diameter) in the cells of the stratum perintestinale as well as in the adjacent parenchyma cells. These spherules remained unstained when tested for zinc, calcium, ferric iron, copper, and inorganic phosphate in both wax and fresh-frozen sections. In oblique fresh-frozen sections the cytoplasm of the stratum perintestinale cells took up alizarin red (calcium).

The parenchyma cells of the prosoma of *B. balanoides* were positive for glycogen, deposits being built-up during the spring and summer. Fig. 20a shows a section of the prosoma stained for glycogen whilst Fig. 20b shows an adjacent section similarly stained but after digestion with diastase. The same parenchyma cells also store lipid droplets, the amount varying seasonally. Lipid is absent in the winter (November to March) and particularly prevalent in spring and early summer (April to June). During the summer the droplets became progressively restricted to the regions of the body nearest to the mantle tissues (containing the ovaries) before being lost altogether. No lipid droplets were present in the prosomal parenchyma of *B. hameri* collected in November, although a few were present in March. In addition to glycogen and lipid, the prosomal parenchyma of *B. balanoides* contained glycoprotein globules, 1–15  $\mu\text{m}$  in diameter (see Table V): their presence varied seasonally, being present from March to mid-summer and like the lipid droplets, being lost from the body – apparently to the mantle tissues.

#### PANCREATIC GLANDS

All the species studied have a pair of pancreatic glands, each being connected to the anterior midgut by means of a pancreatic duct (see Fig. 21, *Octolasmis lowei*). In *Balanus balanoides* and *B. hameri* the glands lie outside the caeca laterodorsalia, at times also overlapping the caeca lateroventralia (nomenclature after Törnävä, 1948).



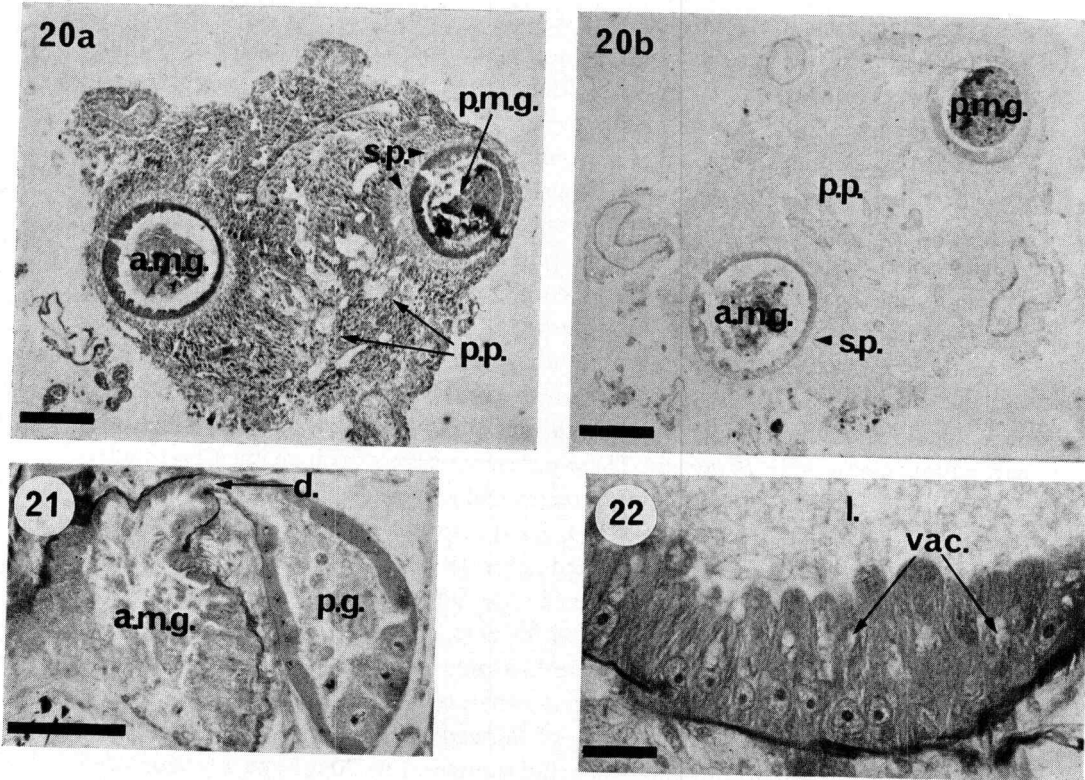


Fig. 20. *Balanus balanoides*: a, section through a prosoma after staining for glycogen (Best's carmine); scale bar, 200  $\mu\text{m}$ ; b, control section stained for glycogen after pre-treatment with diastase; scale bar, 200  $\mu\text{m}$ : glycogen present throughout the prosomal parenchyma (p.p.) but conspicuously absent from the stratum perintestinalis (s.p.): a.m.g., anterior midgut; p.m.g., posterior midgut.

Fig. 21. *Octolasmis lowei*: section showing the duct (d.) connecting the pancreatic gland (p.g.) and anterior midgut (a.m.g.): scale bar, 120  $\mu\text{m}$ .

Fig. 22. *Balanus hameri*: pancreatic gland cells: l., lumen of gland; vac., vacuoles: scale bar, 40  $\mu\text{m}$ .

The glands are branched tubular organs composed of large columnar epithelial cells which pass through the cell cycle already described for the epithelium of the midgut itself. When viewed under the light microscope the cells have a distinct apical brush border, large basal nuclei, and rest on a thin basement membrane beneath which there are thin longitudinal and circular muscles. The lumen of each gland contains material apparently derived from the detached apical regions of the lining epithelial cells. Apical vacuoles (3–8  $\mu\text{m}$  diameter) were evident in the gland cells of *B. hameri* (Fig. 22) and these apparently contain accumulations of secretory material. Pancreatic duct cells, although smaller, resemble the cells of the glands themselves.

Fig. 23 is an electron-micrograph of a typical pancreatic gland cell of *B. balanoides*. Short microvilli are sparsely distributed at the apical surface. Each cell is packed with rough endoplasmic reticulum which is highly swollen apically owing to the accumula-

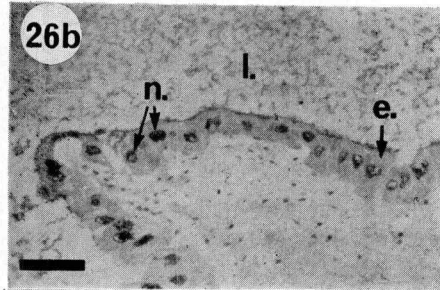
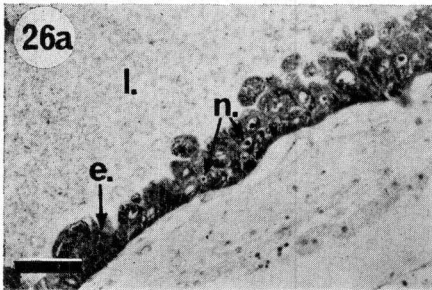
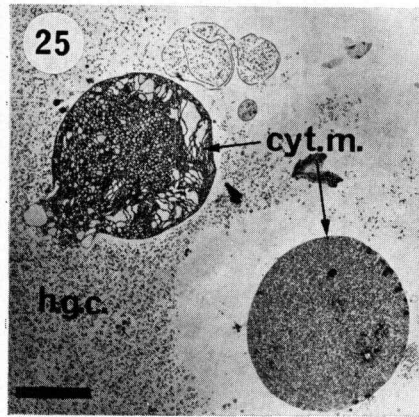
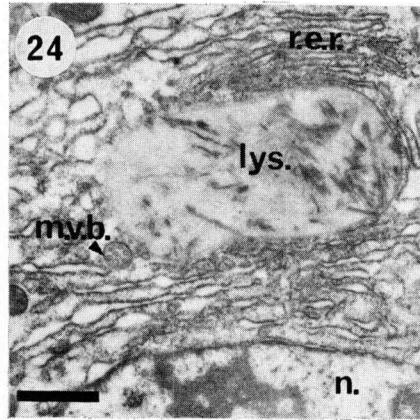
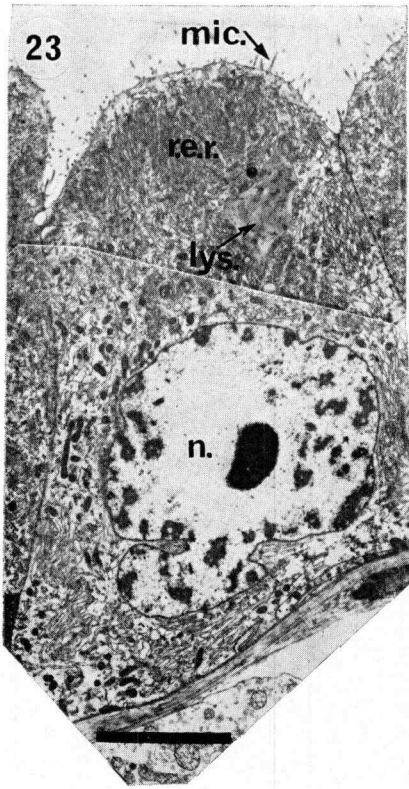


Fig. 23. *Balanus balanoides*: electron micrograph of pancreatic gland cell showing apical microvilli (mic.), large nucleus (n.), and rough endoplasmic reticulum (r.e.r.); lys., lysosome: scale bar,  $6 \mu\text{m}$ .

Fig. 24. *Balanus balanoides*: high power electron micrograph of a lysosome (lys.) within a pancreatic gland cell: m.v.b., multivesicular body; n., nucleus; r.e.r., rough endoplasmic reticulum: scale bar,  $0.75 \mu\text{m}$ .

Fig. 25. *Balanus balanoides*: electron micrograph showing the 'cytoplasmic' masses (cyt. m.) in the lumen of the pancreatic gland: h.g.c., homogeneous granular contents: scale bar,  $10 \mu\text{m}$ .

Fig. 26. *Balanus hameri*: a, pancreatic gland cells stained with Methyl-Green-Pyronin (M-G-P); scale bar,  $70 \mu\text{m}$ ; b, control section after pretreatment with RNAase: e., epithelium of pancreatic gland; l., lumen of pancreatic gland; n., nuclei: scale bar,  $70 \mu\text{m}$ .

TABLE VI  
Histochemical characteristics of the pancreatic glands of *Balanus hameri*.

Test	Lumen contents	Microvillous region	Apical vacuoles	Cytoplasm		Nucleus	
				Apical	Basal	Nucleolus	Chromatin
Bromphenol Blue	—	—	++	+	+	++++	+++
DMAB	++	++	++	+	+	—	—
Diazo	+++	+	++	+	+	+	+
DDD (SH/SS)	+++	+	+++	—	—	—	—
DDD (SH)	—	+	+	+	+	—	—
Baker's	+	+	—	+	—	—	—
PAS	+	++	+	+	—	+	+
PAS/diastase	+	++	+	+	—	+	+
Hale's	—	++	—	—	—	+	+
Mucihematein	+	++	—	+	—	++++	+
Alcian Blue pH 1.0	—	—	—	—	—	+++	+++
Alcian Blue pH 2.5	—	+++	—	++	—	—	—
Alcian Blue pH 2.5/RNAase	—	+++	—	—	++	—	+
Methyl-Green-Pyronin	—	+	—	—	—	—	+
M-G-P/RNAase	—	+	—	++++	++++	++++	+++
M-G-P/DNAase	—	+	—	—	—	—	+++
Feulgen	—	+	—	++++	++++	++++	—
Toluidine Blue	—	Turquoise	—	—	—	+++	++
Azure A	—	Turquoise	—	—	—	—	—
Azan	Blue	Blue/Brown	Faint Blue	Red/Brown	Red/Brown	—	—
						Red	Red

BR R500C PL DP PP 01 02 F90V

tion of secretory material. The cells also contain multivesicular bodies (0.3  $\mu\text{m}$  diameter) apically, Golgi bodies, lysosomes, and dark bodies. The lysosomes (1–4  $\mu\text{m}$  diameter) are irregularly shaped with heterogeneous contents (Fig. 24). Dark bodies (0.4  $\mu\text{m}$  diameter) contain small densely packed vesicles with electron-dense contents. Nuclei are large and often lobulated. As may be seen from Fig. 25 the gland lumen contents consist in part of cytoplasmic masses which are the budded off apical regions of the epithelial cells (apocrine secretion; see Kurosumi, 1961). These masses are usually packed with highly swollen rough endoplasmic reticulum and presumably disintegrate to give the remaining contents of the gland lumen (Fig. 25).

The histochemical reactions of the pancreatic glands of *B. hameri* are given in Table VI. The cytoplasm of the cells contains much RNA. (Fig. 26). The apical vacuoles contain proteinaceous material as does the gland lumen. It appears, therefore, that pancreatic gland cells are highly active protein-secreting cells. The identification at the electron microscope level of the irregularly shaped cell organelles as lysosomes is confirmed by enzyme histochemistry. The pancreatic cells of both *Balanus* species contain small discrete areas positive for acid phosphatase and non-specific esterase (also for leucine aminopeptidase in *B. hameri*). Discrete alkaline phosphatase activity was also localized in the cytoplasm with at times a weak general activity apically. The gland cells however showed little evidence for the presence of digestive carbohydrases or proteases. Both species gave negative results for  $\alpha$ -glucosidase and the gland cells of *B. hameri* alone showed leucine aminopeptidase activity, and that inconsistently. The cytoplasm of the pancreatic gland cells of *B. balanoides* showed a weak general positive reaction to esterase.

#### HINDGUT

Törnävä (1948) divided the cuticle-lined hindgut of *B. improvisus* into four regions but the hindgut of both *B. balanoides* and *B. hameri* is more conveniently divided into two. The posterior midgut leads to a much folded muscular region of the hindgut which effectively acts as a sphincter. This region leads posteriorly into a wide chamber (the anal chamber) from which the slit-like anus opens. The hindgut and foregut are similar histologically (see Törnävä, 1948) and the histochemical characteristics of the hindgut are similar to those already described for the foregut. The folded epithelial layer of the anterior region of the hindgut is tall compared with the non-folded thin epithelium of the anal chamber. The cuticular lining is not simple and in the anterior folded region there are often small setules (3–5  $\mu\text{m}$  long) extending into the lumen.

In each of the stalked barnacle species the hindgut is simpler than that of *Balanus*. A distinct sphincter separates the posterior midgut and hindgut, and this is small compared to the compressed anterior region of the *Balanus* hindgut. The hindgut has a final wide chamber, the anal chamber, as in *Balanus*.

## DISCUSSION

The secretions of barnacle salivary glands bind food material prior to ingestion (Gruvel, 1893a). The suboesophageal gland is in such a position that its secretion would come into contact with material being passed forward from the second and later pairs of cirri to the oral cone and first cirri. The labial gland secretion mixes with the food as it reaches the mouthparts. The secretions of the salivary glands do not have a common chemical composition. The suboesophageal gland of *B. hameri* and both glands of *B. balanoides* secrete a glycoprotein but the labial glands of *B. hameri* secrete an acid mucopolysaccharide. Both glands of *Chelonibia testudinaria* and the suboesophageal gland of *Lepas anatifera* secrete proteinaceous material. In addition the salivary secretions of *Lepas hilli* and *Balanus perforatus* contain tyrosine (protein) (Thomas, 1944) and the histochemical characteristics of the salivary gland secretions of *Chthamalus stellatus* (Bocquet-Védrine & Ovechko, 1960) indicate a glycoprotein. The labial glands of *Lepas anatifera* distinctively produce two different secretions – one proteinaceous and the other an acid mucopolysaccharide – apparently in a fixed pattern in each group of four cells.

Both glycoproteins and mucopolysaccharides may be major constituents of mucous secretions (Gottschalk & Graham, 1966; Hunt, 1970) and so either would be able to carry out the rôle of food-binding. It appears surprising that two chemically different secretions would perform an identical rôle in a single species such as *Balanus hameri* or *Lepas anatifera*. It is possible, therefore, that in these species at least the secretions do not act solely as food-binding material. The glycoprotein secretions may be digestive enzymes as found by Got & Marnay (1968) for the snail *Helix pomatia*. Another possible interpretation is that the situation found in the labial glands of *Lepas anatifera* represents an ancestral crustacean cycle of mucous secretion and that the production of a single secretory product (either glycoprotein or acid mucopolysaccharide) is a secondary specialization. Evidence for this second interpretation is found in the work of Gabe (1960) on three groups of epidermal salivary glands in the isopod, *Anilocra physodes*, where two of these groups of glands produce both acid mucopolysaccharide and glycoprotein as part of one secretory cycle.

The cells of the pancreatic glands of all the barnacle species investigated were histologically distinct from those of the midgut and midgut caeca when present. This may not represent the situation in all barnacles since Gruvel (1893b) has described intermediate hepatopancreatic cells, *e.g.*, in *Conchoderma virgatum*. The epithelium of the caeca of *Balanus* is identical with that of the rest of the midgut and the caeca probably represent simple extensions of midgut surface area. As reviewed by Törnävä (1948), earlier authors have interpreted the histology of the midgut epithelium in several ways. Monterosso (1923) described the cycle of cell formation in the midgut of *B. perforatus* and this cell cycle agrees well with the situation in the midgut, midgut caeca, and pancreatic glands. Törnävä (1948) described two kinds of epithelial cells in the midgut of *B. improvisus* – those showing balloon secretion and

cells without it. This interpretation could not be applied to any of the species examined here and Törnävä is inconsistent when illustrating balloon secretion. One illustration (Fig. 41, Plate VI, Törnävä, 1948) shows extrusion of mature epithelial cells as described by Monterosso (1923) and the following illustration (Fig. 42, Plate VI, Törnävä, 1948) shows material emerging from a regular columnar epithelium – perhaps representing the secretion of the peritrophic membrane.

The epithelia in all midgut regions have ultrastructural features typical of absorptive cells. There are many long microvilli at the base of which are small vesicles (probably pinocytotic vesicles) which coalesce and continue to increase in size (possibly by combining with primary lysosomes) in the cell. The cells contain lysosomes in addition to accumulations of intracellular lipid and many mitochondria. Apical tight junctions ensure that there is no direct uptake into the intercellular space. The basement membrane shows some infolding. The histochemical evidence for glycogen and lipid accumulation indicates that absorption occurs in all regions of the midgut, while the sites of lipid accumulation suggest that the anterior midgut and caeca are the major absorbing regions, although absorption by the posterior midgut may also be significant. The midgut epithelium also secretes the peritrophic membrane and may be the source of some digestive enzymes, which are released when mature cells disintegrate on being extruded from the epithelium. This appears to be the situation in the posterior midgut where the high apical concentration of esterase in the epithelium (as seen under the light microscope) appears to be related to the presence of mature apical cells laden with lysosomes just before extrusion (as seen with the electron microscope).

The peritrophic membrane of both *Balanus* species contains both mucopolysaccharides and proteins. These histochemical results agree with De Mets & Jeuniaux (1962) who found that certain insect peritrophic membranes consist of between 21 and 47 % protein and between 3.7 and 12.9 % chitin, and also contain mucopolysaccharides. Similarly Peters (1968) has found that peritrophic membranes consist of chitin-containing microfibrils in a mucoprotein ground substance; Richards & Richards (1971) described the peritrophic membrane of *Aedes aegypti* as containing a chitin-protein complex.

The cells of the most posterior region of the midgut of barnacles contain acid mucopolysaccharide granules apically and these when secreted may 'lubricate' the passage of the faecal pellet on extrusion through the hindgut. Other granules containing ferric iron are present in the midgut cells of *Lepas anatifera*, *Pollicipes mitella*, and *Balanus hameri*, and may be equivalent to the few electron-dense spherules in the midgut epithelium of *B. balanoides*. Walker *et al.* (1975a) have detected iron in midgut cell granules of *L. anatifera* by X-ray microanalysis.

All regions of the midgut epithelium rest on an elastic basal lamina, so that it is surrounded by an elastic envelope which maintains its shape and acts against contracting circular muscles. Mabillot (1954) found similar elastic tissue in the basal membrane of the midgut of the amphipod *Gammarus pulex*.

The ultrastructure of tissue directly beneath the midgut basal lamina of balanid barnacles has been investigated in detail by Koulisch (1971, 1976). He has described the structure of the processes leading from the stratum perintestinale cells to the midgut epithelium and concluded that they are involved in transport. Since large amounts of glycogen are present in the adjacent parenchyma, it was surprising that no glycogen was found in the stratum perintestinale of *B. balanoides*. The cytoplasm does stain strongly with mucihematein and this might represent carbohydrate material in transit to parenchyma cells. Furthermore, carbohydrate may be translocated across the stratum perintestinale cells in the form of free sugars before being converted to glycogen in the parenchymatous tissue. Such sugars would be lost during processing. The parasomal corpuscles have similar histochemical characteristics to the parasomes ('Nebenkern') of the gland cells of salamanders and snails (Gabe, 1958) and probably contain nucleoprotein, the 'Nebenkern' being closely associated with the ergastoplasm (rough endoplasmic reticulum) of the cell (Hague-nau, 1958). The large spherules in the stratum perintestinale cells and prosoma parenchyma cells of barnacles have been described by Walker *et al.* (1975a, b) who found that they consist mostly of zinc phosphate. The granules did not, however, stain histochemically for zinc or inorganic phosphate. This lack of staining suggests that the granules are impermeable and may reflect a possible rôle as non-toxic accumulations of waste material.

The parenchyma cells in the prosoma contain seasonally varying amounts of glycogen, lipid, and glycoprotein globules. Barnes, Barnes & Finlayson (1963) found metabolic reserves to be built up on renewed feeding in spring and early summer, and lipid and glycogen levels increased slightly in the autumn after the release of gametes, perhaps in response to an autumnal planktonic bloom. Barnes & Blackstock (1975) furthermore found an increase in alkaline phosphatase activity in barnacle body tissue, apparently associated with metabolic processes induced by the spring increase. Lipid droplets and glycoprotein globules are accumulated in the same cells and in late summer both are lost from the body possibly to the mantle surrounding the ovaries. Eggs and first stage nauplii later contain this lipid and glycoprotein as constituents of the yolk (Rainbow & Walker, unpubl.) which is probably a glycolipovitellin as in many other crustaceans.

The cells of the pancreatic glands have large nuclei and RNA-rich cytoplasm and the ultrastructural characteristics of active secretory cells. Proteinaceous material accumulates apically before being released into the gland lumen. The discrete localization of acid phosphatase, esterase, and occasional leucine aminopeptidase activity in the pancreatic gland cells may be interpreted as lysosomal, and alkaline phosphatase activity is probably indicative of ribosomal protein synthesis. Rainbow (unpubl.) has found high concentrations of amylase and protease in the pancreatic glands, and so it would appear that the pancreatic glands secrete digestive enzymes.

The foregut and hindgut play little part in digestion and absorption. Histochemical evidence in this study is consistent with the observation that the epithelial cells secrete

a cuticular lining, part of which is later resorbed (see Davis, Fyhn & Fyhn, 1973). The variability of the histochemical results is probably a result of the metabolism of these cells relative to the moulting cycle.

## ACKNOWLEDGEMENTS

We wish to thank Professor D. J. Crisp, for his help and encouragement during this work, and Drs Ll. G. Gruffydd, L. J. Rees, and J. A. Nott for advice on the manuscript. We are grateful for much editorial assistance. We also thank Mr D. C. Williams for photography, Mrs S. C. Walker for ultramicrotomy, and Mr D. A. Davies for technical assistance with the electron microscope. One of us (P.S.R.) held a N.E.R.C. studentship during this work.

## REFERENCES

- BARNES, H., M. BARNES & D. M. FINLAYSON, 1963. The seasonal changes in body weight, biochemical composition, and oxygen uptake of two common boreo-arctic cirripedes, *Balanus balanoides* and *B. balanus*. *J. mar. biol. Ass. U.K.*, Vol. 43, pp. 185–211.
- BARNES, H. & J. BLACKSTOCK, 1975. Seasonal changes in the non-specific phosphatase activities and their relation to other metabolic activities in *Balanus balanoides* (L.) and *B. balanus* (L.). In, *Proc. 9th Europ. mar. biol. Symp.*, edited by H. Barnes, Aberdeen University Press Ltd, Aberdeen, pp. 287–298.
- BOCQUET-VÉDRINE, J. & N. OVECHKO, 1960. Contribution à l'étude des "glandes salivaires" de *Chthamalus stellatus* (Poli). *Bull. Soc. linn. Normandie*, T. 10, pp. 106–118.
- CASSELMAN, W. G. B., 1962. *Histochemical technique*. Methuen, London, pp. 31–44.
- CHAYEN, J., L. BITENSKY & R. G. BUTCHER, 1973. *Practical histochemistry*. John Wiley & Sons, London, 271 pp.
- DAVIS, C. W., U. E. H. FYHN & H. J. FYHN, 1973. The intermolt cycle of cirripeds: criteria for its stages and its duration in *Balanus amphitrite*. *Biol. Bull. mar. biol. Lab., Woods Hole*, Vol. 145, pp. 310–322.
- DE METS, R. & C. JEUNIAUX, 1962. Sur les substances organiques constituant la membrane péritrophiqne des insectes. *Archs int. Physiol. Biochim.*, T. 70, pp. 93–96.
- ELDER, H. Y. & G. OWEN, 1967. Occurrence of "elastic" fibres in the invertebrates. *J. Zool. Lond.*, Vol. 152, pp. 1–8.
- GABE, M., 1953. Sur quelques applications de la coloration par la fuchsine paraldéhyde. *Bull. Microsc. appl.*, T. 3, pp. 153–162.
- GABE, M., 1958. Caractères histochimiques des parasomes de certaines cellules glandulaires. *C.r. hebd. Séanc. Acad. Sci., Paris, D*, T. 247, pp. 1907–1909.
- GABE, M., 1960. Données histochimiques sur les glandes exocrines céphalothoraciques d'*Anilocra physodes* Leach. *Annls Histochem.*, T. 5, pp. 55–63.
- GOMORI, G., 1952. Histochemistry of esterases. *Int. Rev. Cytol.*, Vol. 1, pp. 323–335.
- GOT, R. & A. MARNAY, 1968. Isolement, purification, et quelques caractéristiques physicochimiques de deux  $\beta$ -hexosidases du suc digestif d'*Helix pomatia*. *Europ. J. Biochem.*, Vol. 4, pp. 240–246.
- GOTTSCHALK, A. & E. R. B. GRAHAM, 1966. The basic structure of glycoproteins. In, *The proteins*, edited by H. Neurath, Academic Press, New York and London, Vol. IV, Ch. 19.
- GRAY, P., 1954. *The microtometist's formulary and guide*. Constable and Co., London, 794 pp.
- GRUVEL, A., 1893a. Sur l'armature buccale et une nouvelle glande digestive des Cirrhipèdes. *C.r. hebd. Séanc. Acad. Sci., Paris*, T. 117, pp. 858–861.
- GRUVEL, A., 1893b. Contribution à l'étude des Cirrhipèdes. *Archs Zool. exp. gen.*, 3e serie, T. 1, pp. 401–610.
- HAGUENAU, F., 1958. The ergastoplasm: its history, ultrastructure, and biochemistry. *Int. Rev. Cytol.*, Vol. 7, pp. 425–483.



- HOROBIN, R. W., L. FLEMMING & I. M. KEVILL-DAVIES, 1974. Basic fuchsin-ferric chloride: a simplification of Weigert's resorcin-fuchsin stain for elastic fibres. *Stain Technol.*, Vol. 49, pp. 207-210.
- HUNT, S., 1970. *Polysaccharide-protein complexes in invertebrates*. Academic Press, London, 329 pp.
- KOULISH, S., 1971. Fine structure at the basal surface of intestinal epithelium in the midgut region of the Balanidae, with special reference to "neural-like" processes. *J. Morph.*, Vol. 135, pp. 1-12.
- KOULISH, S., 1976. Organization of 'special' parenchymal cells underlying the midgut in some barnacles. *J. exp. mar. Biol. Ecol.*, Vol. 23, pp. 155-170.
- KRAMER, H. & G. M. WINDRUM, 1955. The metachromatic staining reaction. *J. Histochem. Cytochem.*, Vol. 3, pp. 227-237.
- KRÜGER, P., 1940. Dr H. G. Bronn's Klassen und Ordnungen des Tierreichs. Bd V, 1. Abt., 3. Buch, Teil III; Cirripedia. 1-560 pp. Leipzig.
- KUROSUMI, K., 1961. Electron microscopic analysis of the secretion mechanism. *Int. Rev. Cytol.*, Vol. 11, pp. 1-124.
- LASKEY, A. M., 1950. A modification of Mayer's Mucihematein technic. *Stain Technol.*, Vol. 25, pp. 33-34.
- LISON, L., 1936. *Histochimie animale. Méthodes et problèmes*. Gauthier-Villars, Paris, 320 pp., see pp. 139-160.
- MABILLOT, S., 1954. Particularités histologiques de la membrane basale du mésentéron chez *Gammarus pulex* (L.). *C.r. hebd. Séanc. Acad. Sci., Paris, D*, T. 238, pp. 1378-1379.
- MAZIA, D., P. A. BREWER & M. ALFERT, 1953. The cytochemical staining and measurement of protein with mercuric bromphenol blue. *Biol. Bull. mar. biol. Lab., Woods Hole*, Vol. 104, pp. 57-67.
- MONTEROSSO, B., 1923. Rinnovamento dell'epitelio e significatio delle peighe nella mucosa dell'intestino de *Balanus perforatus* Bruguière. *Archo ital. Anat. Embriol.*, T. 20, pp. 253-271.
- MONTEROSSO, B., 1926. Contributo alla conoscenza del parasoma. *Boll. Soc. Biol. sper.*, T. 1, pp. 318-320.
- MONTEROSSO, B., 1927. Su di un particolare strato cellulare esistente attorno al mesointestino dei Balanidi. *Atti Accad. naz. Lincei R. (Sci. Fis., Mat. e Nat.)*, T. 2, Fasc. XV, pp. 402-436.
- PEARSE, A. G. E., 1960. *Histochemistry, theoretical and applied*. Vol. 1. J. & A. Churchill Ltd, London, 2nd edition, 1008 pp.
- PEARSE, A. G. E., 1968. *Histochemistry, theoretical and applied*. J. & A. Churchill Ltd, London, 3rd edition, 759 pp.
- PEASE, D. C., 1964. *Histochemical techniques for electron microscopy*. Academic Press, New York, 2nd edition, 381 pp.
- PETERS, W., 1968. Vorkommen, Zusammensetzung und Feinstruktur peritrophischer Membranen im Tierreich. *Z. Morph. Oköl. Tiere*, Bd 62, S. 9-57.
- RICHARDS, A. G. & P. A. RICHARDS, 1971. Origin and composition of the peritrophic membrane of the mosquito, *Aedes aegypti*. *J. insect Physiol.*, Vol. 17, pp. 2253-2275.
- SMYTH, J. D., 1954. A technique for the histochemical demonstration of polyphenol oxidase and its application to egg-shell formation in helminths and byssus formation in *Mytilus*. *Q. Jl microsc. Sci.*, Vol. 95, pp. 139-152.
- THOMAS, H. J., 1944. Tegumental glands in the Cirripedia Thoracica. *Q. Jl microsc. Sci.*, Vol. 84, pp. 257-282.
- TÖRNÄVÄ, S. R., 1948. The alimentary canal of *Balanus improvisus* Darwin. *Acta zool. fenn.*, Vol. 52, pp. 1-52.
- WALKER, G., P. S. RAINBOW, P. FOSTER & D. J. CRISP, 1975a. Barnacles: possible indicators of zinc pollution? *Mar. Biol.*, Vol. 30, pp. 57-65.
- WALKER, G., P. S. RAINBOW, P. FOSTER & D. L. HOLLAND, 1975b. Zinc phosphate granules in tissue surrounding the midgut of the barnacle *Balanus balanoides*. *Mar. Biol.*, Vol. 33, pp. 161-166.
- WALLEY, L. J., 1967. The cirral glands: a new type of epidermal gland in cirripedes. *Crustaceana*, Vol. 12, pp. 151-158.